

CASE REPORT

Recurrent Epididymo-orchitis: A Clinical Presentation of Posterior Urethral Valve in a Child with Down Syndrome

Faizah MZ¹, Noorakmal A¹, Syariz IS², Dayang AA², Tan HL²

Department of ¹Radiology and ²Surgery, Faculty of Medicine, Universiti Kebangsaan Malaysia, Kuala Lumpur

ABSTRAK

Injap uretra posterior biasanya dikesan pada kanak-kanak baru lahir. Kami melaporkan seorang pesakit sindrom Down yang didiagnosa dengan injap uretra posterior pada usia 5 tahun. Beliau mendapat komplikasi injap uretra posterior iaitu infeksi berulang organ testis dan epididimis sebagai gejala awal penyakit tersebut. Kes ini akan membincangkan presentasi luar biasa penyakit injap uretra posterior pada pesakit sindrom Down, cara mendiagnosanya dan komplikasi akibat penyakit tersebut sekiranya tidak dirawat.

Kata kunci: Injap uretra posterior, sindrom Down, infeksi epididimis dan testis

ABSTRACT

Posterior urethral valve (PUV) commonly presents during infancy. We report a case of a 5-year-old boy with Down syndrome who was diagnosed to have PUV in late childhood. He presented with recurrent left epididymo-orchitis, an uncommon but recognized complication of PUV. Our aim is to discuss this rare and delayed presentation of PUV in particular amongst children with Down syndrome, method of diagnosis and complication of the disease if left untreated.

Key words: posterior urethral valve, Down syndrome, epididymo-orchitis

INTRODUCTION

Children with Down syndrome have four to five times higher risk of developing renal and urinary tract anomalies as compared to the general population (Kupferman et al. 2009). These anomalies include renal hypoplasia, hydronephrosis, ureterovesical and uropelvic junction obstruction, vesicoureteric reflux (VUR) and posterior urethral valves

(PUV). Of these, PUV is the least common anomaly (Narasimhan et al. 2005).

Usually, PUV is detected during the prenatal or neonatal period. However, delay in presentation and diagnosis of PUV in particular in Down syndrome (DS) has been reported recently (Kupferman et al. 2009 & Culty et al. 2007). This is contributed by lack of awareness of the association between PUV and DS (Narasimhan et al. 2005).

Address for correspondence and reprint requests: Faizah Mohd Zaki. Department of Radiology, Universiti Kebangsaan Malaysia Medical Center, Jalan Yaacob Latiff, 56100 Cheras, Kuala Lumpur. Tel: 03-9145 6177. Fax: 03-91456682. Email: drfaizah@ppukm.ukm.my

With this in mind, we present a child with Down syndrome who had recurrent orchitis as the initial presentation of a posterior urethral valve that had a delayed diagnosis.

CASE REPORT

CKS is 5-year-old Chinese boy who was delivered via Caesarean section at 37 weeks period of gestation (POG) with a birth weight of 2.87kg. His mother was a 32-year-old lady gravida 2 para 0+1 (with one history of abortion). She had gestational diabetes mellitus and was referred to our institution at 26 weeks POG. She was started on subcutaneous insulin injection for her diabetic treatment at 35 weeks POG. Fetal echocardiography revealed a fetal cardiac anomaly. An amniocentesis and karyotyping was done at 35 weeks POG that revealed a male fetus with trisomy 21.

Postnatally, he was admitted to the neonatal intensive care unit (NICU) for cardiac evaluation and treatment because he had signs and symptoms of cardiac failure with scalp oedema and bilateral pedal oedema. An echocardiography was done and revealed a large ventricular septal defect (VSD), atrial septal defect (ASD) and a small patent ductus arteriosus (PDA). He was treated for the cardiac failure during his stay in the NICU. He underwent corrective cardiac surgery at the age of 5 months old.

He was diagnosed to have left orchitis at the age of one year when he presented with a left inguinal pain and swelling. An ultrasound of the renal tract and scrotum revealed bilateral undescended testes at the inguinal region with evidence of increased colour Doppler flow of the left testis indicating orchitis (Figure 1). Both of his kidneys were normal. His urine FEME showed presence of leucocytes but the urine culture was negative. His renal profile was normal. His condition improved with a course of antibiotics. A micturating

cystourethrography (MCU) was planned but the patient did not turn up for the appointment. Later, he had another episode of orchitis at the age of 5 when he presented with left inguinal swelling. There was no history of difficult urination or urinary dribbling.

Clinically, he was afebrile. His left inguinal region was swollen and tender. Biochemical investigations showed normal renal profile and urine culture. An ultrasound showed similar findings as his previous presentation. Micturating cystourethrography was requested in-view of the recurrent orchitis, which revealed a posterior urethral valve. There was no vesicoureteric reflux (Figure 2).

The patient subsequently underwent cystoscopy. Intraoperative findings showed a type I posterior urethral valve associated with glanular hypospadias. The bladder neck, bladder outline and both ureteric orifices were normal. The PUV was fulgurated at 4 and 8 o'clock position with a resectoscope. The child was well post-operatively.

DISCUSSION

Down syndrome (DS) is a common chromosomal disorder. There is an increased risk of congenital abnormalities, including cardiac, eye, and gastrointestinal defects. Genitourinary tract abnormalities however, are not often highlighted (Kupferman et al. 2009; Narasimhan et al. 2005).

Kupferman et al. (2009) reported that the prevalence of renal and urinary tract anomalies in children with Down syndrome was 3.2% as compared to the general population, which is 0.7%. This included, in descending frequency: hydronephrosis, hydroureter, hypospadias, renal agenesis, cystic dysplastic kidney, posterior urethral valve, anterior urethral obstruction and prune belly syndrome.

There were few cases of PUV in DS reported, which presented at a variable

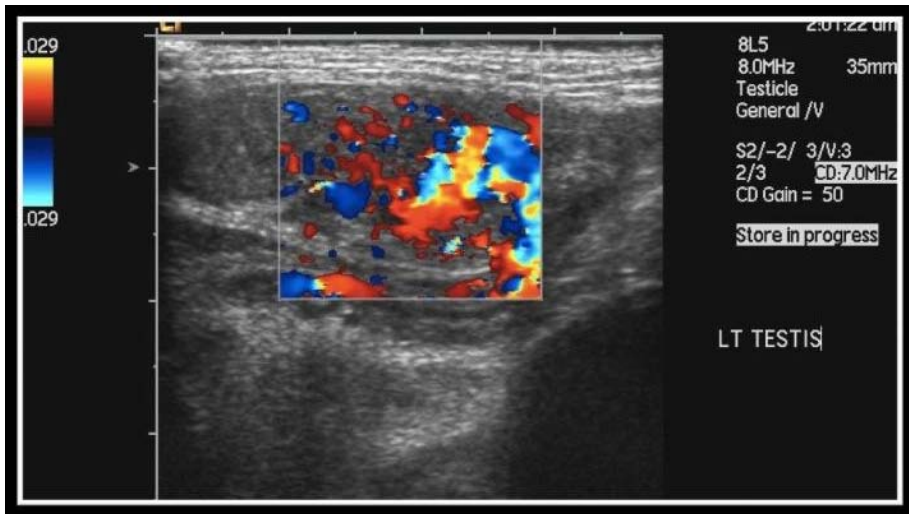


Figure 1: Ultrasound of the left testis which demonstrates an increase in doppler signal within the testis. The left testis is in the inguinal canal.

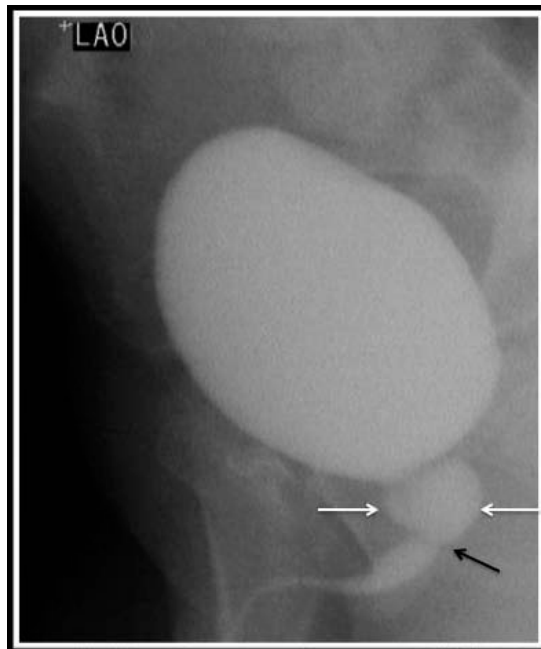


Figure 2: Voiding phase of micturating cystourethrogram (MCU) in left anterior oblique (LAO) view which shows bulbous dilatation of the posterior urethra (white arrows) with transverse linear filling defect distal to it representing a posterior urethral valve (black arrow).

range of age (Kupferman et al. 2009 & Narasimhan et al. 2005). A retrospective study done from year 1992-2004 revealed that there were only two PUV cases amongst 123 patients with Down syndrome with underlying renal and urinary tract anomalies (Kupferman et al. 2009). On the other hand, Narasimhan et al. (2005) reported that six out of 230 patients with PUV had Down syndrome. Their age of presentation ranged between 18 months to seven years. He concluded that in view of the mental retardation and other social problems, families of patients with Down syndrome might not report the poor urinary stream, which contributes to the delay in the diagnosis. The diagnosis of PUV in this patient was delayed, as there was no subsequent follow-up in the clinic. Therefore, further investigations of the epididymo-orchitis (EO) was not done.

There are many different clinical presentations of PUV. Most patients presented with urinary incontinence/ dribbling, obstructive uropathy and urinary tract infection (Kupferman et al. 2009; Narasimhan et al. 2005 & Culty et al. 2007). Khalid et al. (2001) reported that the presentation of PUV is variable whereby 27% of patients were diagnosed by antenatal ultrasound, 30.4% presented with urinary tract infection, 32.4% of patients had history of poor urinary stream, 7.4% of patients had retention of urine in neonatal life and 2.8% had symptoms of renal impairment. Our patient was diagnosed as PUV after he presented with recurrent EO. Surprisingly, he did not have any symptoms of bladder outlet obstruction. A study done among non-DS children with PUV showed that 7.1% of cases presented with recurrent urinary tract infection had history of recurrent EO (Ikuerowo et al. 2008). Abbas et al. (2008) reported a case of PUV in a 4-year-old non-DS child who presented with right scrotal swelling and was diagnosed to have EO. There was no docu-

mented symptoms of bladder outlet obstruction. He had a history of urinary tract infection at the age of three years old. We postulate that the recurrent left EO was likely due to reflux of urine through the ejaculatory duct and vas deferens into the epididymis and testis, which caused chemical irritation.

Generally, PUV was diagnosed early antenatally, during newborn or infancy (Belman et al. 2002). Antenatally, PUV can be diagnosed by identifying typical 'key-hole' appearance of the distended bladder and the dilated posterior urethra. Postnatally, ultrasound scan demonstrates dilated posterior urethra, bilateral hydronephrosis and/ hydroureters, thick-walled urinary bladder and bladder diverticuli. Micturating cystourethrography (MCU) will further delineate the anatomy of the urethra and shows transverse filling defect in the posterior urethra, which represents the membrane of the PUV (Belman et al. 2002; Ikuerowo et al. 2008). Traditional teaching suggests EO is rare in children. It has been recommended that all boys with EO should undergo investigation of the urinary tract. The investigation varies with some centers, which include renal tract ultrasound, cystograms, cystoscopy, and/or urodynamics (McAndrew et al. 2002).

Posterior urethral valve obstruction is a significant cause of renal-related morbidity in male children. Obstructive uropathy from congenital obstructive posterior urethral membrane results in end stage renal disease in 30-40% of patients and is a common indication for renal dialysis and transplantation in patients less than 5 years of age (Ikuerowo et al. 2008). Fortunately, this complication did not present in our patient. He was lucky since he has no vesicoureteric reflux which is one of the favourable prognostic factor in PUV (Belman et al. 2002). A study done by Kukreja et al. (2001) reported that 29% of 70 PUV patients had renal insufficiency at the end of a 3-year

follow-up. He found out that factors found to be statistically significant were age at intervention more than two years, recurrent urosepsis, bilateral high grade vesico-ureteric reflex, bilateral parenchymal damage as seen on ultrasonography and nadir serum creatinine of more than 0.8 mg% (p value <0.05). Therefore, this patient has to be closely monitored to assess progression of his renal function in order to prevent renal insufficiency later.

CONCLUSION

It is important to diagnose PUV early especially in DS patients as the obstructive symptoms may not be evident at clinical presentation. With the association between DS and PUV as well as other renal and urinary tract anomalies, patients with Down syndrome should be screened by doing ultrasound of the renal tract followed by micturating cystourethrogram (MCU) if abnormal.

REFERENCES

- Abbas, M., Nahid, R., Seyed-Taher, E., Nematollah, A., Parvin M., Abdolmohammad, K., Javad, J., Mastaneh, M., Alireza, S. & Marzieh, H. 2008. Posterior urethral valve in a child presenting as recurrent epididymo-orchitis. *Arch Iranian Med* **11**(6): 662-664.
- Belman, A.B., King, L.R. & Kramer, S.A. 2002. *Clinical pediatric urology*. 4th edition. London: Martin Dunitz Ltd, Taylor & Francis group. 929-933.
- Culty, T., Barry-Delonchamps, N., Dorninique, S., Servin, F., Ravery, V. & Boccon-Gibod, L. 2007. Posterior urethral valve in adult with Down syndrome. *Urology* **69**(1): 202.
- Ikuerowo, S.O., Balogun, B.O., Akintomide, T.E., Ikuerowo, A.O.A., Akinola, R.A., Gbelee, H.O. & Esho, J.O. 2008. Clinical and radiological characteristics of Nigerian boys with posterior urethral valves. *Pediatr Surg Int*. **24**:825–829
- Khalid, F.N., Salah R.E., Castro, R.E., Jehad, M.A.D., Ahmad, M.A., Abdullah, A. & Hassan, A. 2001. Presentation of Posterior Urethral Valves in Saudi Arabia in the 90's. *Saudi J Kidney Dis Transpl* **12**(4): 516-519.
- Kukreja, R.A., Desai, R.M., Sabnis, R.B., Patel, S.H. & Desai, M.R. 2001. Outcome of children with posterior urethral valves: Prognostic factors. *Indian J Urol* **17**:141-4
- Kupferman, J.C., Druschel, C.M. & Kupchik, G.S. 2009. Children with Down syndrome had increased risk for renal, urinary tract anomalies. *Pediatrics* **124** : e615- e621.
- McAndrew, H.F., Pemberton, R., Kikiros, C.S. & Gollow, I. 2002. The incidence and investigation of acute scrotal problems in children. *Pediatr Surg Int* **18**: 435–437
- Narasimhan, K.L., Kaur, B. & Marwaha, R.K. 2005. Posterior urethral valve in patients with Down syndrome. *Indian J Pediatr* **72**:802.